



# Acute effect of myofascial reorganization of the trapezius muscle in peripheral muscle oxygenation in asymptomatic subjects – a case series.

Larissa Sinhorim<sup>1</sup>, Mayane Amorim<sup>1</sup>, Laureani Jaques Torres<sup>2</sup>, Janaína Wagner<sup>1</sup>, Nathália Tiepo Niza<sup>1</sup>, Francisco De Paula Lemos<sup>1</sup>, Verônica Vargas Horewicz<sup>3</sup>, Anelise Souza<sup>1</sup>, Gilmar Moraes Santos<sup>1</sup>.

## ABSTRACT

**Background:** Myofascial Reorganization (MFR) is a physiotherapy technique that mixes myofascial pressures and slips and has been used as a simple and non-invasive method that readjusts soft tissues, as well as myofascial adhesions and contractures that may cause decreased blood supply and consequently of physical activity. **Objective:** To verify if the MFR alters the tissue oxygenation of the trapezius muscle (TM) in subjects without the pain symptom in the evaluation day. **Methods:** The sample consisted of eight subjects with a mean age of 23 ( $\pm 6$ ) years and a body mass index of 23.2 ( $\pm 15.0$ ) kg.m<sup>-2</sup>. Changes in muscle oxygenation were measured by near infrared spectroscopy (NIRS) (Portamon, Artinis, the Netherlands) in TM before and after 15 minutes of intervention. The proposed MFR protocol lasted approximately 10 minutes and consisted of pressures, stretching and myofascial slippage of the upper, middle and lower TM fibers. Data normality was performed using the Shapiro Wilk test and due to the parametric nature of the data, the paired t-test was used for pre and post intervention comparison. **Results:** There was a significant increase in the tissue saturation index (TSI) in the trapezius muscle (80.7 $\pm$ 2.7% vs. 89.4 $\pm$ 4.6%;  $p=0.002$ ) in the pre and post intervention comparison. The pre-post variation delta of oxyhemoglobin - O<sub>2</sub>Hb (8.1 $\pm$ 11.2 g/dL), deoxyhemoglobin - HHb (-0.72 $\pm$ 1.6 g/dL) and total hemoglobin - tHB (7.4 $\pm$ 12.3 g/dL) showed no significant difference. However, there was an increase in O<sub>2</sub>Hb, tHB levels and a decrease in HHb. **Conclusion:** The findings showed that the MFR applied on trapezius muscle increased the TSI, which reflects on peripheral muscle oxygenation in subjects without pain in the day of evaluation.

**Keywords:** Myofascial Release; Physical Therapy Modalities; Mechanotransduction; Oxygen Level.

## CASE PRESENTATION

Daily activities with the use of the upper limbs, such as cleaning services, manual or labor activities, sports and recreation may be performed incorrectly, which may lead to adhesions and contractures, causing shoulder and neck pain<sup>(1)</sup>. In addition, psychosocial factors may influence these musculoskeletal disorders<sup>(2)</sup>. This symptom condition was ranked as the fourth highest condition in terms of total disability<sup>(3)</sup>. Among the possible causes of this pain, there is weakness and incoordination of the stabilizing muscles of the shoulder girdle, such as the lower trapezius, middle trapezius and the rotator cuff muscle group<sup>(4)</sup>. The trapezius muscle (TM) is formed by upper, middle and lower fibers, has a good vascularization<sup>(5)</sup>. It also has a viscoelastic lining called fascia, which belongs to the connective tissue and permeates the entire human body, involving muscles and organs and becoming a unique and continuous structural matrix of

restrictive but adjustable tension<sup>(6)</sup>. This structure is believed to work in “chains” to maintain the integrity of the body<sup>(7)</sup>, having as main characteristic the adaptation to the mechanical forces, ordered or reordered in the sense of the force acting on them<sup>(8)</sup>. Alteration of tissue vascularization could limit or prevent the slipping of myofascial tissues during the imposition of these forces, in the performance of daily functional activities, and may cause adhesions, contractures and pain<sup>(9)</sup>. According to Schleip (2003), myofascial adhesions and contractures decrease blood supply, however, vascularization can be recovered through manual techniques such as Myofascial Reorganization (MFR), reducing tissue compression and pain without compromising muscle endurance<sup>(11)</sup>. This technique merges stretching, manual pressure and slip in the myofascial tissue<sup>(12)</sup>. Thus, influencing mechanoreceptors within the fascia, contributing to changes in local fluid dynamics, capillary constriction and

**Correspondence:** Larissa Sinhorim. Endereço: Pascoal Moreira Cabral Leme, Balneário Camboriú – Santa Catarina – Brasil. E-mail: larissasinhorim@hotmail.com. Telefone: (47) 98405-7340

<sup>1</sup> Universidade do Estado de Santa Catarina. Santa Catarina, Florianópolis, Brasil.

Full list of author information is available at the end of the article.

**Financial Support:** The authors declare that there was financial support by FAPESC (2017TR764 and 2019TR602)

**Submission date 01 April 2019; Acceptance date 14 May 2019; Publication date 22 November 2019**





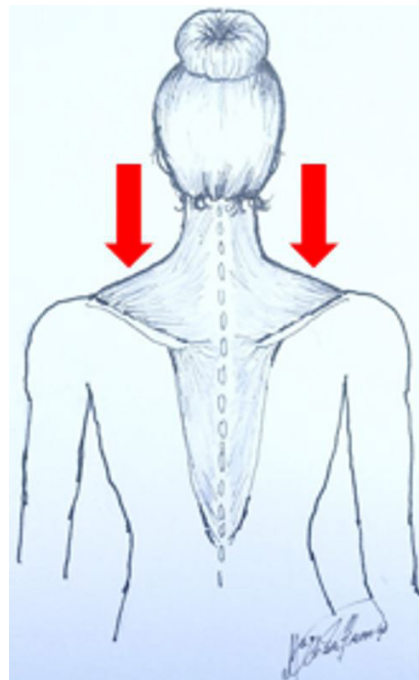
increasing local blood flow<sup>(10)</sup> restoring the normal integrity of these tissues<sup>(13)</sup>. Among the tools available for hemodynamic assessment, near infrared spectroscopy (NIRS) stands out. It is a valid, reliable and non-invasive instrument<sup>(14)</sup> which can continuously quantify and capture variations in hemoglobin levels (oxygenated, deoxygenated, total hemoglobin) and tissue saturation index of a muscle region<sup>(15,16)</sup>. Although noninvasive hemodynamic evaluation using NIRS was used to investigate peripheral muscle oxygenation<sup>(17)</sup>, to date, no studies have been found regarding variations in peripheral muscle oxygenation after the application of the MFR technique on TM in asymptomatic subjects. In addition, MFR is considered a technique that uses only manual contact, and is considered a simple, low-cost, non-invasive method that adjusts myofascial structures<sup>(18)</sup>. Thus, it is believed that MFR could release tissue restriction with consequent increase in local peripheral muscle oxygenation as well as having substantial applicability in clinical practice. Given the above, the aim of this study was to investigate the effect of MFR on oxyhemoglobin (O<sub>2</sub>Hb), deoxyhemoglobin (HHb), total hemoglobin (tHB), and Tissue Saturation Index (TSI) of trapezius muscle in college subjects without pain on the day of assessment. The sample was selected by convenience and non-probabilistically. Eight subjects who agreed to participate in the study were recruited and signed an informed consent form. Research Ethics Committee number: 2.630.855.

**Evaluation Procedure**

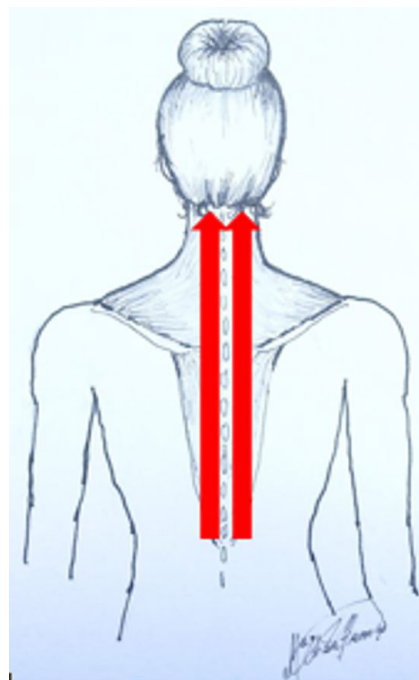
For the pre and post intervention measurement of O<sub>2</sub>Hb, HHb, tHB and TSI, it was used the NIRS, for this, the skin was cleaned with alcohol and the device was positioned 50% between the medial edge of the scapula and the spine, at the level of the third thoracic vertebra (T3), on the right middle TM fibers (dominance). For the positioning of the optode, the subjects had the area of interest bare so as not to alter the collected data or to hinder the application of the technique. In addition, the equipment was covered with a black cloth to prevent light penetration and interference with signal collection. The acquisition frequency was 10 Hz and the time to collect peripheral muscle oxygenation was one minute before the intervention and one minute after 15 minutes of the end of the intervention.

**Intervention Procedure**

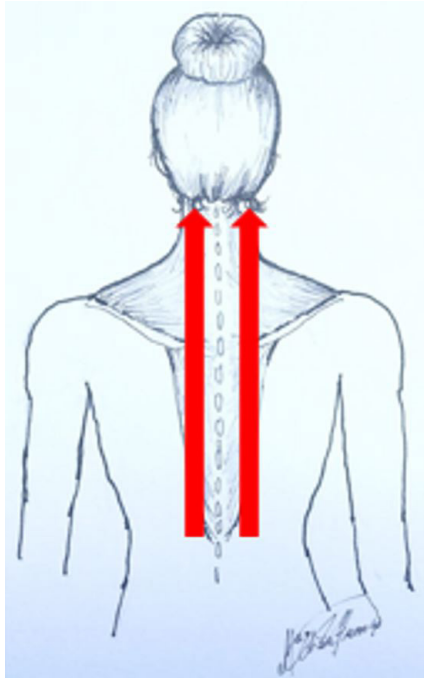
The manual approach was based on Lehmann *et al.*, 1970; Taylor *et al.*, 1990; Scleip *et al.*, 2005; Bienfait, 1999; Myers, 2010 and Prentice, 2011. The Myofascial Reorganization protocol described below and represented by Figure 1,2,3,4,5,6,7,8,9,10,11 was adapted by a physiotherapist with expertise in Manual Therapies and with over 15 years of clinical experience. The steps were:



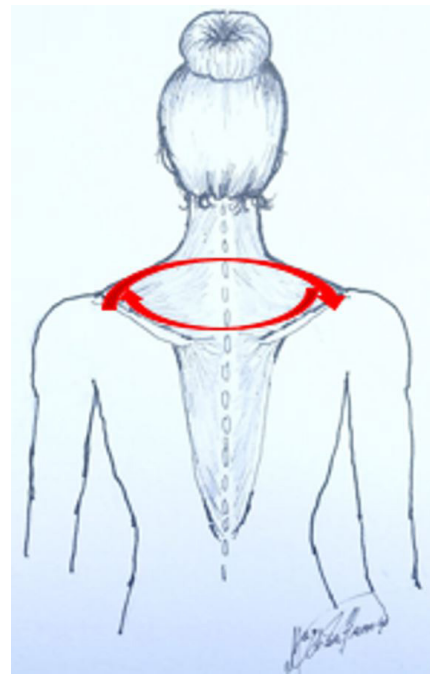
**Figure 1** – The Myofascial Reorganization protocol. Note: Patient in lateral position, without pillow and with 90° of knee and hip flexion. The physiotherapist standing at the head of the gurney and with the right olecranon fixed on the anterior superior iliac spine (elbow 90°) and with the right hand in fist exerted caudal pressure with the TM proximal phalanges on the patient’s upper fibers on both sides for a minute and a half each.



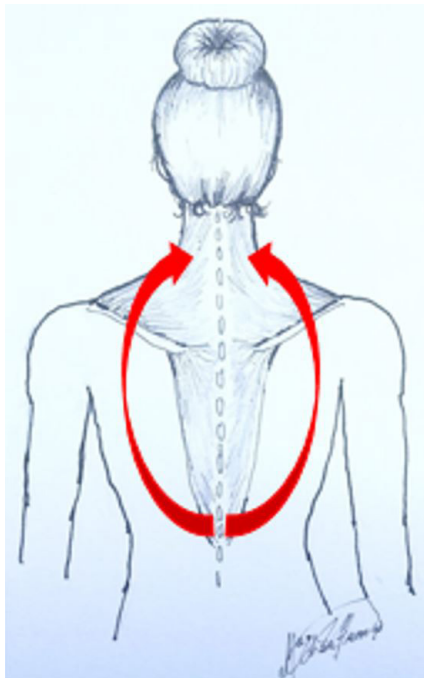
**Figure 2** – The Myofascial Reorganization protocol. Note: Patient in prone position, without pillow, with frontal region of the head resting on the dorsal region of the hands. The physiotherapist was standing at the head of the gurney and performed the following steps: A) Distance of two centimeters from the T12 vertebra, index and middle finger of both hands exerted simultaneous pressure and deep sliding towards the base of the skull three times.



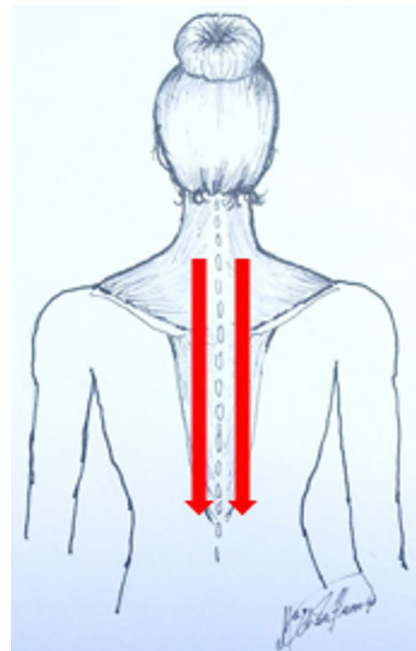
**Figure 3** – The Myofascial Reorganization protocol. Note: Patient in prone position, without pillow, with frontal region of the head resting on the dorsal region of the hands. The physiotherapist was standing at the head of the gurney and performed the following steps: B) Distance of four centimeters from the T12 vertebra, index and middle finger of both hands exerted simultaneous pressure and deep sliding towards the base of the skull three times.



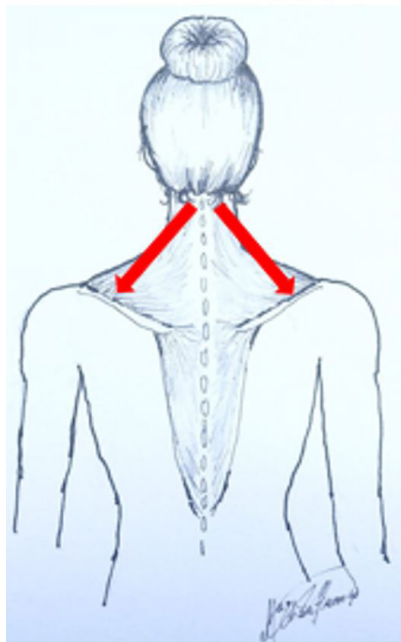
**Figure 5** – The Myofascial Reorganization protocol. Note: Patient in prone position, without pillow, with frontal region of the head resting on the dorsal region of the hands. The physiotherapist was standing at the head of the gurney and performed the following steps: D) The physiotherapist's thumb fixed on the individual's acromion and with the other thumb performed the pressure and the deep sliding towards the other acromion through T3. Then, returned to the first position through T1, forming a "canoe", on both sides three times each.



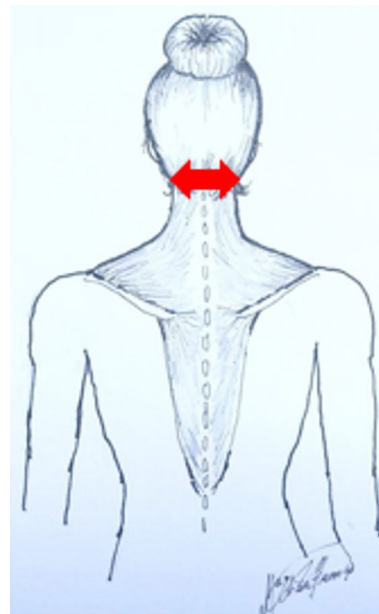
**Figure 4** – The Myofascial Reorganization protocol. Note: Patient in prone position, without pillow, with frontal region of the head resting on the dorsal region of the hands. The physiotherapist was standing at the head of the gurney and performed the following steps: C) Distance of six centimeters from the T12 vertebra, index and middle finger of both hands exerted simultaneous pressure and deep sliding towards the acromion bypassing both shoulder blades three times.



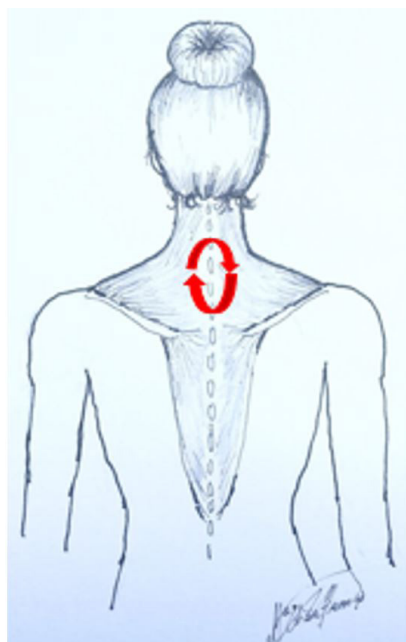**Figure 6** – The Myofascial Reorganization protocol. Note: Patient in prone position, without pillow, with frontal region of the head resting on the dorsal region of the hands. The physiotherapist was standing at the head of the gurney and performed the following steps: E) The physiotherapist's hand positioned at the base of the skull and with the contralateral thenar region performed pressure and sliding caudally from the upper trapezius to the lower trapezius. This protocol was performed on both sides three times.



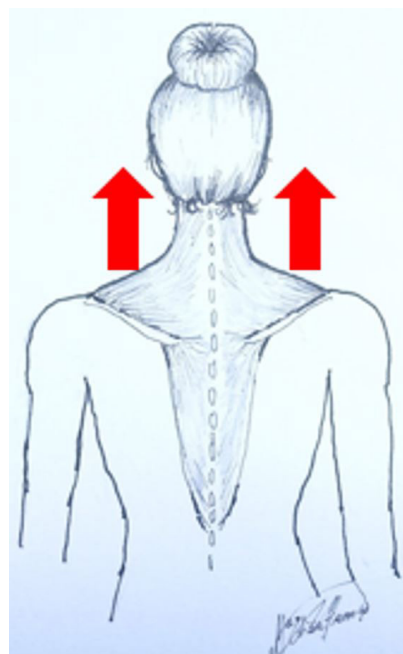
**Figure 7** – The Myofascial Reorganization protocol. Note: Patient in prone position, without pillow, with frontal region of the head resting on the dorsal region of the hands. The physiotherapist was standing at the head of the gurney and performed the following steps: F) The physiotherapist’s hand positioned at the base of the skull and with contralateral thumb performed pressure and sliding from C3 to distal insertion of trapezius upper fibers. This protocol was performed on both sides three times.



**Figure 9** – The Myofascial Reorganization protocol. Note: Patient in prone position, without pillow, with frontal region of the head resting on the dorsal region of the hands. The physiotherapist was standing at the head of the gurney and performed the following steps: H) Thumbs were positioned at the base of the skull (distal insertion of the trapezius upper fibers) horizontally in relation to the spine, obtaining contact between the distal phalanges. Subsequently, pressure and lateral traction of the fascia were exerted in opposite directions.

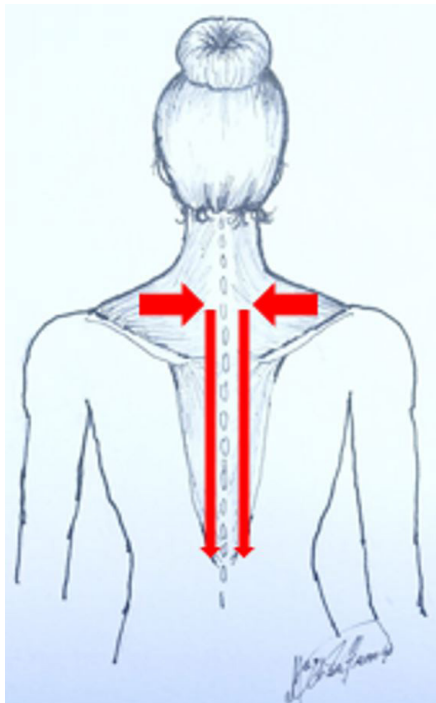


**Figure 8** – The Myofascial Reorganization protocol. Note: Patient in prone position, without pillow, with frontal region of the head resting on the dorsal region of the hands. The physiotherapist was standing at the head of the gurney and performed the following steps: G) Thumbs were positioned at T1 exerting circular pressure and sliding in opposite directions.



**Figure 10** – The Myofascial Reorganization protocol. Note: Patient in supine position, without pillow, with towel roll in cervical concavity with upper and lower limbs in neutral position. With the physiotherapist standing at the head of the gurney and with the thumbs positioned above the clavicles and the other fingers resting on the posterior mass of the trapezius upper fibers, the fibers were perpendicularly detached in the cranial direction for one and a half minutes.





**Figure 11** – The Myofascial Reorganization protocol. Note: With the patient sitting on the chair, with 90° flexion of the hip and knees, the physiotherapist supported with the head of the metacarpals the nuchal region along the spinous process from T1 to T12 and exerting pressure, sliding and detachment (“vertical “fold” over the spinous processes of the cervical and thoracic vertebrae) in caudal direction three times each. During sliding, the patient is instructed to perform cervical flexion slowly and continuously.

### Statistical analysis

The analyzes were conducted using the Statistical Package for the Social Sciences software (SPSS v. 20.0). For data analysis, Shapiro-Wilk normality tests were applied. Due to the parametric nature of the data, the paired t test was performed for dependent analyzes (pre and post). A significance level of 5% ( $p < 0.05$ ) was adopted in all tests. The sample (Table 1) was composed of four males and four females, physiotherapy students, with a mean age of 22.62 ( $\pm 5.96$ ) years and Body Mass Index (BMI) of 23.26 ( $\pm 15.0$ ) kg/m<sup>2</sup>. The collection was performed in the biomechanics laboratory of Health and Sports Science Center at Santa Catarina State University in environment with controlled temperature between 22 and 24°C.

### RESULTS

In the verification of the peripheral muscle oxygenation variables of the TM in the evaluated subjects, there was a significant increase in the tissue saturation index ( $\Delta\text{TSI}$ :  $8.7 \pm 5.7$ ;  $p = 0.002$ ) in the pre and post intervention comparison (Table 2). The varying levels of oxyhemoglobin  $\Delta\text{O}_2\text{Hb}$  ( $8.1 \pm 11.2$  g/dL;  $p = 0.08$ ), deoxyhemoglobin  $\Delta\text{HHb}$  ( $-0.72 \pm 1.6$  g/dL;  $p = 0.24$ ) and total hemoglobin  $\Delta\text{tHB}$  ( $7.4 \pm 12.3$  g/dL;  $p = 0.13$ ) did not show significant differences

in pre and post intervention comparison. However, there was an increase in  $\text{O}_2\text{Hb}$  and tHB levels and a decrease in HHb (Table 3).

### DISCUSSION

This study aimed to investigate the effect of MFR on oxyhemoglobin ( $\text{O}_2\text{Hb}$ ), deoxyhemoglobin (HHb), total hemoglobin (tHB) and Tissue Saturation Index (TSI) of the trapezius muscle in college subjects without pain on the day of assessment. The results of this study showed that the TSI increased significantly after the intervention while the other outcome variables,  $\text{O}_2\text{Hb}$ , HHb and tHB, showed no significant change. However, these evidenced increase ( $\text{O}_2\text{Hb}$ , tHB) and decrease (HHb) in the levels pre and post-intervention comparison. These findings suggest an improvement in peripheral muscle oxygenation measured after 15 minutes of intervention by the proposed protocol, corroborating the results found by Schah et al. <sup>(17)</sup> (2016), which described an increase in lumbar paravertebral muscle oxygenation in asymptomatic subjects 30 minutes after the application of the protocol listed by the study. Even in the case of asymptomatic subjects, daily activities with the use of the upper limbs improperly performed can trigger the appearance of adhesions and contractures<sup>(1)</sup>, causing a decrease in peripheral muscle oxygenation. These adhesions and contractures are characterized by the proliferation of local fibroblasts and their differentiation into myofibroblasts in myofascial tissue and compared to fibroblasts, the myofibroblasts regulate the expression of mild muscle actin (SMA)<sup>(25,26)</sup> and increase the production of extracellular matrix proteins such as collagen of type I, III, VI and V. In addition, myofibroblasts increase the expression of tissue metalloproteinase inhibitors, resulting in reduced activity of enzymes that degrade extracellular matrix<sup>(26)</sup>, and may eventually make it more rigid, resulting in decreased blood supply. This decrease could limit or prevent the sliding of myofascial tissues with one another, causing a failed cycle, and resulting in altered functionality and pain<sup>(9)</sup>. Additionally, it is known that myofascial adhesions may decrease blood supply, however, vascularization may be altered through manual interventions that would cause tissue remodeling through mechanotransduction, a process by which cells convert mechanical stimuli into a chemical response<sup>(21)</sup>.

The protocol used in the present study is based on studies<sup>(19-24)</sup> and it is based on the fact that manipulation of myofascial structures can increase metabolic rate and restore fluidity to tissues, and the pressure, stretching and friction that the manipulation produce would increase temperature and tissue energy level to promote more base substances. In addition to manual techniques, when performed correctly in the myofascial tissue, mechanoreceptors within the fascia can be influenced, contributing to changes in local fluid dynamics, capillary constriction and increasing local blood flow, restoring the normal integrity of these tissues<sup>(12,13,21,27)</sup>. Thus, it is possible

**Table 1** – Characterization of the sample.

Subjects	Gender	Age (years)	Height (cm)	Mass (kg)	Dominance	BMI (kg/m <sup>2</sup> )
1 – NA	Male	23	179	77	Right-handed	24.03
2 – FR	Female	23	163	54	Right-handed	20.32
3 – AR	Male	21	170	84	Right-handed	29.07
4 – MM	Female	28	167	64	Right-handed	22.95
5 – VF	Female	22	157	72	Right-handed	29.21
6 – NF	Male	24	172	60.3	Right-handed	20.38
7 – SW	Female	20	167	63	Right-handed	22.59
8 – FL	Male	20	183	58.7	Right-handed	17.53
<b>MEAN</b>	<b>4/4</b>	<b>22.62</b>	<b>169.75</b>	<b>66.62</b>	<b>Right-handed</b>	<b>23.26</b>

**Table 2:** Pre and post intervention values of tissue oxygenation for tissue saturation index, oxyhemoglobin, deoxyhemoglobin and total hemoglobin.

n	O <sub>2</sub> Hb g/dL pre	O <sub>2</sub> Hb g/dL post	HHb g/dL pre	HHb g/dL post	tHB g/dL pre	tHB g/dL post	TSI % pre	TSI % post
1	1.73	0.55	-0.03	0.73	1.70	1.28	82.71	82.92
2	2.19	2.28	1.04	0.10	3.23	2.38	76.70	87.54
3	4.18	15.94	2.33	2.78	6.51	18.72	84.93	90.00
4	15.13	4.68	6.12	2.15	21.25	6.83	81.28	90.71
5	-2.77	11.41	15.82	15.41	13.05	26.82	79.64	94.96
6	30.99	51.81	31.04	30.54	62.03	82.35	82.70	91.30
7	16.00	37.66	22.36	23.13	38.36	60.79	78.92	94.63
8	48.97	57.10	43.46	41.50	92.43	98.59	78.72	83.26

Note: Values presented as one minute mean pre and post. TSI: Tissue Saturation Index; O<sub>2</sub>Hb: oxyhemoglobin; HHb: deoxyhemoglobin; tHB: total hemoglobin.

**Table 3:** Values of tissue oxygenation variation between post and pre-intervention for tissue saturation index, oxyhemoglobin, deoxyhemoglobin and total hemoglobin.

Oxygenation	Mean + SD	p value
ΔTSI (%) Post-Pre	8.7 ± 5.7	0.002
ΔO <sub>2</sub> Hb (g/dL) Post-Pre	8.1 + 11.2	0.08
ΔHHb (g/dL) Post-Pre	-0.72 + 1.6	0.24
ΔtHB (g/dL) Post-Pre	7.4 + 12.3	0.13

Note: Values presented as means and standard deviations (SD). TSI: Tissue Saturation Index; O<sub>2</sub>Hb: oxyhemoglobin; HHb: deoxyhemoglobin; tHB: total hemoglobin.

that the MFR may have acted in the alteration of the structural constitution of the fascia through mechanotransduction<sup>(12,13)</sup>, causing a change in oxygenation of the trapezius muscle. It is a fact the clinical use of these resources in physiotherapy practice, suggesting that the application of an external mechanical stimulus, through manual techniques such as MFR, including the protocol proposed in this study, could be used to reduce and/or prevent the formation of adhesions and contractures<sup>(28)</sup>, favoring tissue regeneration. However, results of manual interventions specifically on peripheral muscle oxygenation of this soft tissue require further study, as the effectiveness of manual techniques has not yet been objectively proven<sup>(12)</sup>. In this sense, a systematic review by

Ajimsha et al. (2014) showed the variation in the quality of the studies between moderate and high among the 19 clinical trials analyzed. Of these, nine showed that MFR was better than non-treatment or sham treatment for various musculoskeletal and painful conditions. With the present study, it was observed that the number of subjects and the presence of a control group were limiting factors. However, this study refers to preliminary data from a randomized controlled clinical trial.

## CONCLUSION

The findings showed that the MFR applied to the trapezius muscle increased the IST, which reflects on peripheral muscle oxygenation in subjects without the symptom of pain on the day of evaluation.

## CONSENT

The eight asymptomatic participants who agreed to participate signed the informed consent form.

## AUTHORS' CONTRIBUTIONS:

MA, NTN, LJT, JW and FPL performed the data collection; GMS performed the statistical analysis; MA and LA: writing of the article; GMS, AS and VVH: Correction of the manuscript. All authors read and approved the final manuscript



## CONFLICTS OF INTEREST:

The authors declare that there was no conflict of interests.

## AUTHORS DETAILS

<sup>2</sup> Universidade do Vale do Itajaí. Santa Catarina, Itajaí, Brasil. <sup>3</sup> Universidade do Sul de Santa Catarina, Palhoça, Brasil.

## REFERENCES

- Soggard K, Fallentin N, Nielsen J. Work load during floor cleaning. The effect of cleaning methods and work technique. *Eur. J. Appl. Physiol. Occup. Physiol.* 1996, 73 (1–2): 73-81.
- Freitas, Fabiana Cristina Taubert de. *A ginástica Laboral na redução de queixas de estresse ocupacional e dor osteomuscular em funcionários administrativos de uma universidade pública*. Diss. Universidade de São Paulo, 2010.
- Hoy D, March L, Woolf A, Blyth F, Brooks P, Smith E et al. "The global burden of neck pain: estimates from the global burden of disease 2010 study." *Ann Rheum Dis.* 2014 Jul; 73(7): 1309-15.
- Stapait EL, Dalsoglio M, Ehlers AM, Santos GM. Fortalecimento dos estabilizadores da cintura escapular na dor no ombro: revisão sistemática; *Fisioter Mov*, 2013. 26(3): 667-75.
- Boushel R, Langberg H, Olesen J, Gonzalas AJ, Bulow J, Kjaer M. Monitoring tissue oxygen availability with near infrared spectroscopy (NIRS) in health and disease. *Scandinavian Journal of Medicine & Science in Sports*, 2001; 11: 213-22.
- Findley T, Schleip R. *Fascia*. Elsevier. 2007.
- Mckenney K, Elder AS, Elder C, Hutchins A. Myofascial Release as a Treatment for Orthopaedic Conditions: A Systematic Review. *J Athl Train.* 2013 Jul-Aug; 48(4): 522-27.
- Findley TW. Fascia research. third international fascia research congress. *Int J Ther Massage Bodywork.* 2010; 3(4): 1-4.
- Lewit K, Olsanska S. Clinical importance of active scars: abnormal scars as a cause of myofascial pain. *Journal of manipulative and physiological therapeutics.* 2004, 27(6): 399–402.
- Schleip R. Fascial plasticity, a new neurobiological explanation. *Journal of Bodywork and Movement Therapy.* 2003; 7, 1: 11-19.
- Prado SS, Oliveira SP. Liberação miofascial para o tratamento cefaleia tensional, 2010, <http://tcconline.utp.br/media/tcc/2017/05/LIBERACAO-MIOFASCIALPARA-O-TRATAMENTO-CEFALEIA-TENSIONAL.pdf>, acessado em: 14/06/2018.
- Ajimsha MS, Daniel B, Chuthra S. Effectiveness of myofascial release in the management of chronic low back pain in nursing professionals. *J Bodyw Mov Ther.* 2014; 14; 18: 273–81.
- Lima L.A. Liberação Miofascial no Tratamento de Nódulos Reumatoides, 2014, [http://portalbiocursos.com.br/ohs/data/docs/34/278\\_LiberaYyo\\_Miofascial\\_no\\_Tratamento\\_de\\_Nódulos\\_Reumatoides.pdf](http://portalbiocursos.com.br/ohs/data/docs/34/278_LiberaYyo_Miofascial_no_Tratamento_de_Nódulos_Reumatoides.pdf), acessado em: 06/05/2018.
- Lima, Alexandre, and Jan Bakker. "Espectroscopia no infravermelho próximo para a monitorização da perfusão tecidual." *Rev Bras Ter Intensiva.* 2011; 23.3: 341-51.
- Ferrari M, Motolla L, Quaresima V. Principles, techniques, and limitation of near infrared spectroscopy. *Canadian Journal of Applied Physiology.* 2004; 29, 463-87.
- Lin JH, Maikala RV, Mcgorry R, Burnette C. NIRS application in evaluating threaded-fastener driving assembly tasks. *International Journal of Industrial Ergonomics.* 2010; 40: 146-52.
- Schah Y, Arkesteijn M, Thomas D, Whyman J, Passfield L. The acute effects of integrated myofascial techniques on lumbar paraspinal blood flow compared with kinesio-taping: A pilot study. *J Bodyw Mov Ther.* 2017; 21(2): 459-467.
- Amorim MS, Sinhorim LMB, Santos GM. Fascia Toracolombar E A Liberação Miofascial Como Tratamento Fisioterapêutico Na Dor Lombar: Revisão De Literatura. *Revista Inspirar.* 2018; 15,1: 44-50.
- Lehmann JF, Masock AJ, Warren CG, Et Al. Effect of therapeutic temperatures on tendon extensibility. *Arch. Phys. Med. Rehabil.* 1970; 50: 481-87.
- Taylor DC, Et Al. Viscoelastic properties of muscle-tendon units: The biomechanical effects of stretching. *Am J Sports Med.* 1990; 18,3: 300-8.
- Schleip R. Active fascial contractility: Fascia may be able to contract in a smooth muscle-like manner and thereby influence musculoskeletal dynamics. *Med Hypotheses.* 2005;65(2):273-7.
- Bienfait M. *Fáscia e pompage*. 4. ed. São Paulo: Summus, 1999.
- Myers TW. *Trilhos Anatômicos*. 2 ed. Rio de Janeiro: Editora Elsevier, 2010.
- Prentice WE. *Fisioterapia na prática esportiva: uma abordagem baseada em competências*. 14.ed. São Paulo: Artmed, 2011.
- Morikawa Y, Takamoto K, Nishimaru H, Taguchi T, Urakawa S, Sakai S, Ono T, Nishjo H. Compression at Myofascial Trigger Point on Chronic Neck Pain Provides Pain Relief through the Prefrontal Cortex and Autonomic Nervous System: A Pilot Study. *Front Neurosci.* 2016; 11: 186-91
- Pardali E, Sanchez-Duffhues G, Gomez-Puerto MC, Ten Dijke P. TGF-β-Induced Endothelial-Mesenchymal Transition in Fibrotic Diseases. *Int J Mol Sci.* 2017 Oct 17;18(10). pii: E2157.
- Cox JM. *Dor lombar: mecanismo, diagnóstico e tratamento*. 6. ed. São Paulo: Manole; 2002.
- Bouffard NA, Cutroneo KR, Badger GJ, White SL, Buttolph TR, Ehrlich HP et al. Tissue Stretch Decreases Soluble TGF-β1 and Type-1 Procollagen in Mouse Subcutaneous Connective Tissue: Evidence From Ex Vivo and In Vivo Models. *J Cell Physiol.* 2008; 214, 2: 389-95