

Infrared thermography in the diagnosis of Achilles tendinitis. A randomized double-blind pilot clinical trial

Rodrigo A. B. Lopes-Martins¹, Luis Filipe Beloni², Maria Célia G. Santos², Felícia C. P. Bueno¹, Pedro S. L. Lopes-Martins³, Ingvill Fjell Naterstad⁴, Jan Magnus Bjordal⁴, Carlos R. Ferreira¹, Alberto S. Sá Filho³, Patrícia S. Leonardo⁵.

¹Laboratory of Biophotonics and Experimental Therapeutics - LABITEX, Evangelical University of Goiás (UniEVANGELICA), Anápolis (GO), Brazil.

²Faculdade de Ciências da Saúde, Universidade do Vale do Paraíba – UNIVAP, São José dos Campos (SP), Brazil.

³Laboratório Integrado de Neurociência e Condicionamento Físico – LINC, Evangelical University of Goiás (UniEVANGELICA), Anápolis (GO), Brazil.

⁴Department of Global Public Health and Primary Care, Universitetet i Bergen, Bergen, Hordaland, Norway

⁵Laboratory of Health Technologies - LATES, Evangelical University of Goiás (UniEVANGELICA), Anápolis (GO), Brazil.

Abstract:

Background: The Achilles tendon (AT) is the widest and most resistant of the osteoarticular system and has the greatest load-bearing capacity. It is involved in daily functioning and sports activities performance. Exposure to excessive stress on the calcaneus tendon (CT) can prevent an effective repair process and favor permanent injuries. Tendinopathy is a clinical syndrome resulting from disorientation of AT fibers, and inflammatory signs characteristic of tendinitis or tissue degeneration present in tendinosis can be found. The condition can manifest itself through functional changes accompanied by clinical signs such as crackling, tenderness, pain and edema. Infrared thermography is used to trace thermographic profiles, capable of detecting thermal changes related to pathologies. **Objectives:** The main goal of this study was to correlate AT region thermograms with clinical and functional characteristics in healthy individuals with CT pathology. **Methods:** The present work consists of a double-blind pilot randomized trial, of qualitative and quantitative nature. Individuals with TC tendinopathy, classified in the Tendinopathy Group (TG) and individuals without tendinopathy, classified in the Control Group (CG) participated. Assessments were performed to characterize the subjects belonging to the TG and CG: anamnesis, infrared thermography, referred pain, crepitation and thickness on palpation, algometry, arch sign test and Royal London Hospital test, pain on passive dorsiflexion, pain on lifting the heel and long jump. **Results:** The results obtained in infrared thermography were consistent with those obtained in the clinical evaluation for TG and GC. The results demonstrate that healthy tendons presented an average temperature difference of 0.24 ± 0.15 °C between legs with a maximal difference of 0.4 °C. On the other hand, unilateral tendinopathy presented an average temperature difference of 1.2 ± 0.9 °C, however, this difference could be as big as 5.1 °C. **Conclusion:** It is concluded that infrared thermography can be used safely and non-invasively to aid in the diagnosis of Achilles tendon tendinopathy.

Keywords: Inflammation; tendinopathy; infrared thermography; Achilles tendon.

Corresponding author: Rodrigo Alvaro Brandão Lopes-Martins
E-mail: ralopesmartins@gmail.com

Received: 19 March, 2023

Accepted: 07 June, 2023

Published: 05 Oct, 2023.

Copyright © 2023. This is an Open Access article distributed under the terms of the Creative Commons Attribution Non-Commercial License which permits unrestricted non-commercial use, distribution, and reproduction in any medium provided article is properly cited.



BACKGROUND

Musculoskeletal diseases, especially joint and tendon diseases, represent a major reason for disability and absences from work in modern society. About 60% of the population over 60 years of age have some type of involvement, especially tendinopathies and osteoarthritis. In addition, there is a significant increase in the practice of physical

activities by the general population, which invariably leads to an increase in the incidence of injuries to the locomotor system^(1, 2).

The incidence of tendon injuries has increased significantly in recent decades, resulting from the greater participation of the population in recreational and competitive physical activities^(1, 2). It is estimated that these injuries comprise 30% to 50% of all sports-related injuries⁽³⁾. Achilles tendon (AT) injuries, for example, affect 50% of elite athletes (mainly runners), 7% to 40% of the population that regularly performs physical activities and 5.9% of sedentary individuals for reasons that are not well determined^(4, 5).

The AT is the widest and most resistant of the osteoarticular system and, therefore, has the highest load bearing capacity^(6, 7). The AT is involved in daily functionality and in the performance of sports activities that exceed the capacity generated by the muscles, such as plyometrics and jumping⁽⁸⁾. The force generated in the AT during the exercise can reach 12 times the body weight, making it vulnerable to repetitive strain injuries⁽⁹⁾. Repeatedly, exposure to excessive stress can impede an effective repair process and then permanent damage will occur⁽¹⁰⁾.

Formed by the union of the gastrocnemius medial and lateral to the soleus (triceps surae), the AT has its insertion in the calcaneal bone and participates in knee flexion and ankle plantar flexion, in addition to helping balance and maintaining posture. Such movements make the AT biologically important for functionality and agility, being responsible for the final stages of the gait step⁽⁸⁾. In addition to acting on daily functionality, the viscoelastic characteristics of AT influence the performance of the musculoskeletal system in activities with shortening-stretching cycles that exceed the capacity generated by the muscles, such as plyometrics and running⁽⁹⁾. The force generated in the AT during exercise can reach 12 times the body weight, making the AT vulnerable to repetitive strain injuries⁽¹⁰⁾.

Achilles tendinopathy is a clinical alteration characterized by the presence of pain and edema in and around the tendon region, thus affecting body biomechanics. It is important to emphasize that pain is the main symptom, however, the mechanism that causes it is still not completely understood. It is possible that there is a relationship with inflammation, which is due to ruptures in collagen fibers⁽¹¹⁾, or that it may originate from a combination of mechanical and biochemical causes⁽¹²⁾.

Among the various risk factors that may predispose Achilles tendinopathy is gender, being more frequent in men⁽¹³⁾, aging⁽¹⁴⁾, overweight, reduced flexibility, discrepancy in the size of the limbs, joint laxity and postural changes. Other risk factors described, especially in cases of AT tendon rupture, are the use of antibiotics such as quinolones⁽¹⁵⁾ and the use of local or systemic corticosteroids⁽¹⁶⁾

Tendinopathy is a clinical syndrome resulting from the disorientation of the AT fibers, with characteristic inflammatory signs. It is related to the tendon itself and surrounding tissues and can be characterized by inflammation, deformation, micro-tears or even ruptures of the structure. The condition can manifest itself through crackling, sensitivity, pain and swelling in the region, in addition to decreased strength and range of motion⁽¹⁷⁾.

According to the mechanical theory of overuse tendinous injuries, from the moment the deformation becomes plastic, micro ruptures occur. Repeatedly, exposure to excessive stress can impede an effective repair process and then permanent damage will occur. There is a consensus in the literature about tendon injuries and their intrinsic and extrinsic multifactors involved. Extrinsic factors are related to repetitive effort, overload and inappropriate use of equipment or shoes, for example. In the intrinsic factors for Achilles' tendinopathy, there are anatomical particularities, such as pes equinus or pes varus or even angulations misaligned postures in the lower limb, muscle weakness or shortening.

Infra-red Thermography

Infrared thermography can be defined as a mode of infrared radiation capture, which uses equipment with a reading in the spectral range between 7 and 12 μm , because this range includes the wavelength range emitted by the human skin, which is about 9,4 μm for the purpose of measuring and indirectly mapping the distribution of the temperatures emitted by the body⁽¹⁸⁾. Human skin was described as a good emitter of Infra-red radiation what makes infra-red thermography a promising tool to enable diagnostics in medical sciences. Mangine et al. (1987)⁽¹⁹⁾ was used to evaluate 17 patients diagnosed with patellar tendinitis. In 2017 Rodriguez-Sanz et al.⁽²⁰⁾ made infrared recordings of 21 sportsmen (elite professional soccer players) before activity and after 30 min of running and demonstrated that infrared thermography was reliable to muscle pattern activation for lower limbs.

Infrared thermography is used to trace thermographic profiles, capable of detecting thermal changes related to pathologies. The aim of this study was to correlate calcaneus tendon (CT) region thermograms with clinical and functional characteristics in healthy individuals and those with CT pathology.

METHODS

Experimental Design and Sample

The present work consists of a double-blind randomized pilot trial of a qualitative and quantitative nature. Individuals with CT tendinopathy, classified in the Tendinopathy Group (TG) and individuals without tendinopathy, classified in the Control Group (CG) participated.

Inclusion and exclusion criteria

Subjects with and without AT were included in the study. For the AT, the inclusion criteria were unilateral or bilateral tendinopathy lasting at least three months, both genders, between 18 and 80 years of age, practicing physical activity or not, and with AT thickening. Those with suturing or previous AT surgery, cortisone injection in the previous six months, systemic inflammatory disease, pregnancy, or familial hypercholesterolemia were excluded. 6 volunteers (n=6) participated in the TG.

For the CG, the inclusion criteria were considered: healthy tendons, both genders, between 18 and 80 years old, practitioners or not of physical activity. Subjects with musculoskeletal diseases or injuries in the lower limbs were excluded. All participants were asked to avoid the use of non-steroidal anti-inflammatory drugs (NSAIDs) in the week prior to the assessment. Six volunteers (n=6) participated in the CG.

Assessments

Assessments were carried out to characterize the subjects belonging to the TGGG and CG. The data collection cycle for everyone took place over the course of a day, respecting the order: anamnesis, infrared thermography, referred pain, crepitus and thickness on palpation, algometry, arch sign test and Royal London Hospital test, dorsiflexion pain passive, pain when lifting the heel and long jump.

Anamnesis

The collection of personal data was performed during the participant's setting. Participants answered several questions about lifestyle habits and injury history.

Infrared Thermography

The infrared thermography technique followed the standards established in the study by Al-Nakhli et al.⁽²¹⁾. Participants were advised to avoid physical exercise and take hot baths before performing the procedure, in order to obtain more reliable data. Each participant remained on the stretcher in prone position, with feet off the stretcher and ankles in a neutral position for 15 to 20 minutes. The room was properly acclimatized with a temperature between 20 and 24°C. The room's windows were covered with black panels, to avoid interference from other light sources in the environment.

The infrared camera was positioned one and a half meters from the participant, at a 45° angle. The equipment used was a ThermoCam FLIR S65HS® camera and the images were analyzed using the ThermoCAM Researcher Pro 2.8 SR-1 software, with a Rain900 color palette, in a temperature range from 18 to 32°C. Four different points were used in the temperature assessment and, the analyzes considered the difference of each point compared to the same contralateral point of everyone.

Referred pain - Visual Analog Scale

The Visual Analog Scale (VAS) was used to measure the intensity of pain in CT tendinopathy, classifying it as mild (0, 1 and 2), moderate (3, 4, 5, 6 and 7) or severe (8, 9 and 10).

Algometry

The test was performed to obtain quantitative information regarding CT sensitivity, using a Von Frey Digital Analgesimeter (EFF 301, INSIGHT). The assessment position was maintained, with the volunteer in the prone position, knees extended and ankles in the neutral position. The evaluator positioned the tip of the equipment on the CT, following an imaginary line perpendicular to the lateral malleolus, and pressure was applied. The participant was instructed to signal in case of pain, and then the pressure was interrupted, and the value shown by the equipment was noted. The procedure was performed three times in a row at each CT.

Crepitation and thickening on palpation.

AT tendinopathy may have a thickening of the tendinous fibers as a symptom, due to the inflammatory process and the fibrinous exudate formed. Thickening of the tendon and underlying tissues causes crepitus. Chronically, inflammation can lead to points of calcification, with reduced elasticity (Masci et al., 2016).

The measurement of signs of thickening and crepitus on palpation was performed with the volunteer lying in ventral decubitus, with knees extended and ankles in a neutral position, to allow plantar flexion and dorsiflexion. The evaluator passively performed the movement of plantar flexion and dorsiflexion, and the test was considered positive for crepitation if there was a clicking sound; positive for thickening if there was an increase in thickness on palpation.

Arc Signal Test

The Arc Sign test verifies whether or not there is CT tendinopathy. The evaluation position was maintained, in ventral decubitus, with extended knees and free ankles, and an active dorsiflexion was requested, followed by an active plantar flexion. The observation of an arch in the muscular belly during the movement indicated movement of edema during the mobilization of the ankle, therefore, positive for CT tendinopathy.

Royal London Hospital Test

The evaluation position was maintained, in ventral decubitus, with extended knees and free ankles, and a maximum active dorsiflexion was requested, followed by a maximum active plantar flexion. The volunteer was asked about pain on movement and if so, the test was positive for CT tendinopathy.

Passive dorsiflexion pain

The evaluation position was maintained, in ventral decubitus, with knees extended and ankles free, and the evaluator performed maximum active dorsiflexion. The volunteer was asked about pain on movement and if so, the test was positive for CT tendinopathy.

Pain on heel lift

The evaluation was performed with the volunteer standing. He was asked to stand in front of the wall in unipodal support, being able to lean on the wall with his upper limbs. The evaluator positioned himself posteriorly to the volunteer, guiding the range of motion using a measuring tape. The heel was raised 1 cm from the floor and then 2 cm from the floor and the volunteer was Test Hospital Royal London. The evaluation position was maintained, in ventral decubitus, with extended knees and free ankles, and a maximum active dorsiflexion was requested, followed by a maximum active plantar flexion. The volunteer was asked about pain on movement and if so, the test was positive for CT tendinopathy.

Passive dorsiflexion pain

The evaluation position was maintained, in ventral decubitus, with knees extended and ankles free, and the evaluator performed maximum active dorsiflexion. The volunteer was asked about pain on movement and if so, the test was positive for CT tendinopathy.

Pain on heel lift

The evaluation was performed with the volunteer standing. He was asked to stand in front of the wall in unipodal support, being able to lean on the wall with his upper limbs. The evaluator positioned himself posteriorly to the volunteer, guiding the range of motion using a measuring tape. The heel was raised 1 cm from the floor and then 2 cm from the floor and the volunteer was asked about pain.

Data analysis

The results obtained were tabulated and analyzed using Microsoft Office Excel 2010® software. Comparisons between the analyzed groups were made by mean and standard deviation of the values obtained.

Ethical aspects

The research project was submitted for analysis by the Ethics and Research Committee (CEP) through Plataforma Brasil and was approved under protocol CAAE: 94820218.2.0000.5503. The study was conducted in accordance with Resolution No. 466/2012 of the National Health Council (CNS). The volunteers were previously oriented

and clarified about the procedures and signed the Free and Informed Consent Form (TCLE).

RESULTS

The study had the participation of 12 volunteers in all, divided between the TG and CG. The mean age of participants without tendinopathy was 26.167 ± 4.74 years. Among the 6 individuals in the CG, 67% were female ($n=4$), 33% male ($n=2$). 67% of participants ($n=4$) practiced some physical activity at least three times a week, while 33% ($n=2$) were sedentary. The TG group consisted of 6 individuals with a mean age of 58.167 ± 7.71 years, of which 50% ($n=3$) were female and 50% ($n=3$) were male. In this group, 83% of participants ($n=5$) practiced physical activity at least three times a week, while 17% ($n=1$) did not. It is possible to verify the characterization of each group in Table 1.

Table 01. Characterization of the control and tendinopathy groups

Group	Age	Gender		Exercise Practice	
		Female	Male	Yes	No
Control	$26.16 \pm 4,74$	67%	33%	67%	33%
Tendinopathy	58.16 ± 7.7	50%	50%	83%	17%

Pain at Rest

The spontaneously referred pain by the volunteer was recorded. The therapist inquired for active pain or any pain at the movement and, was used the VAS. The healthy volunteers reported no pain what means pain = 0. Patients with symptomatic tendinitis we evaluated and inquired for pain at rest or at movement. The Figure 01 demonstrated the results. As we can observe, the TG reported an average level of pain in VAS of 3.6 ± 0.5 .

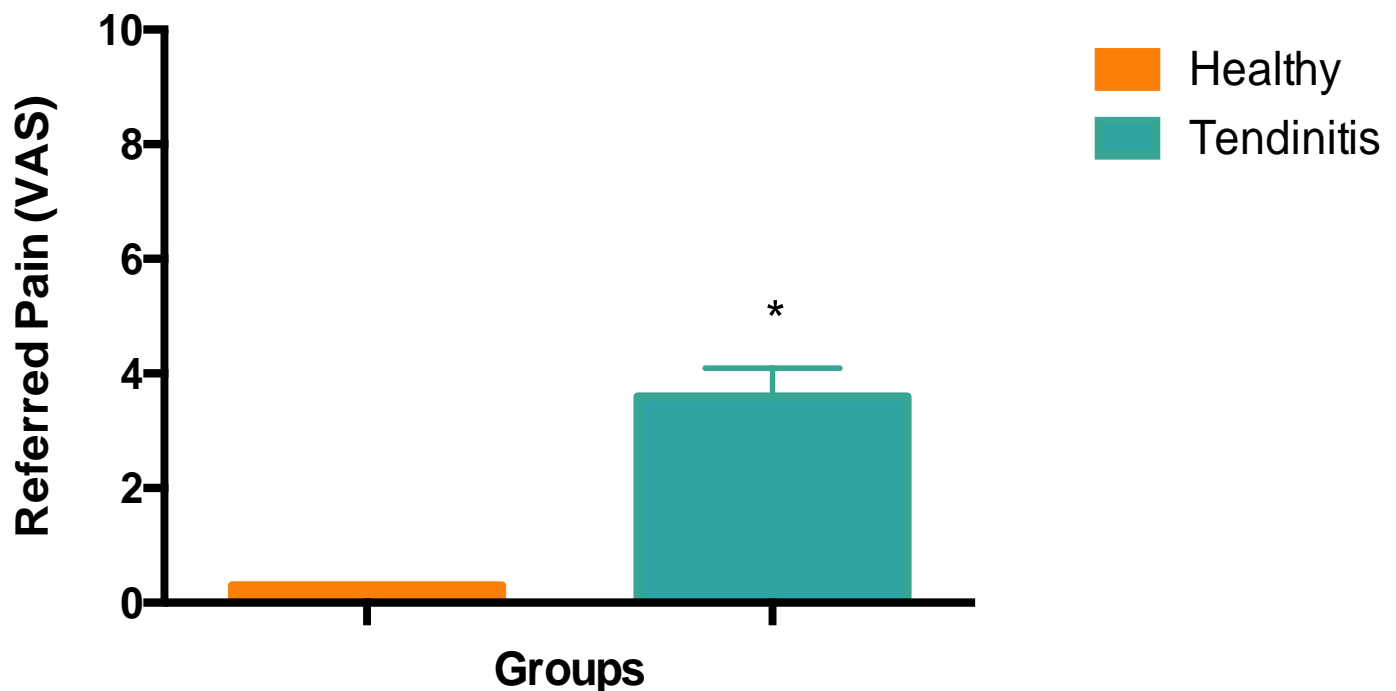


Figure 01: The pain at rest or referred pain was recorded by the Visual Analogue Scale results are expressed as mean \pm stand error of six participants in Control group (healthy tendons) and Tendinitis. * $p < 0.05$.

Pain Threshold

The pain threshold was evaluated with an algometer, and the results are showed in Figure 02. We analyzed both legs and difference between the legs. In Graph 02 we can observe that healthy volunteers presented a pain threshold of $885 \pm 57g$ and $888 \pm 50g$ with no significant difference between the legs. Tendinitis patients presented a pain threshold of $474 \pm 65g$ in the non-affected side and $279 \pm 58g$ on affected side. We could observe a decreased pain threshold even in the non-affected leg and a significant difference between the affected and non-affected leg.

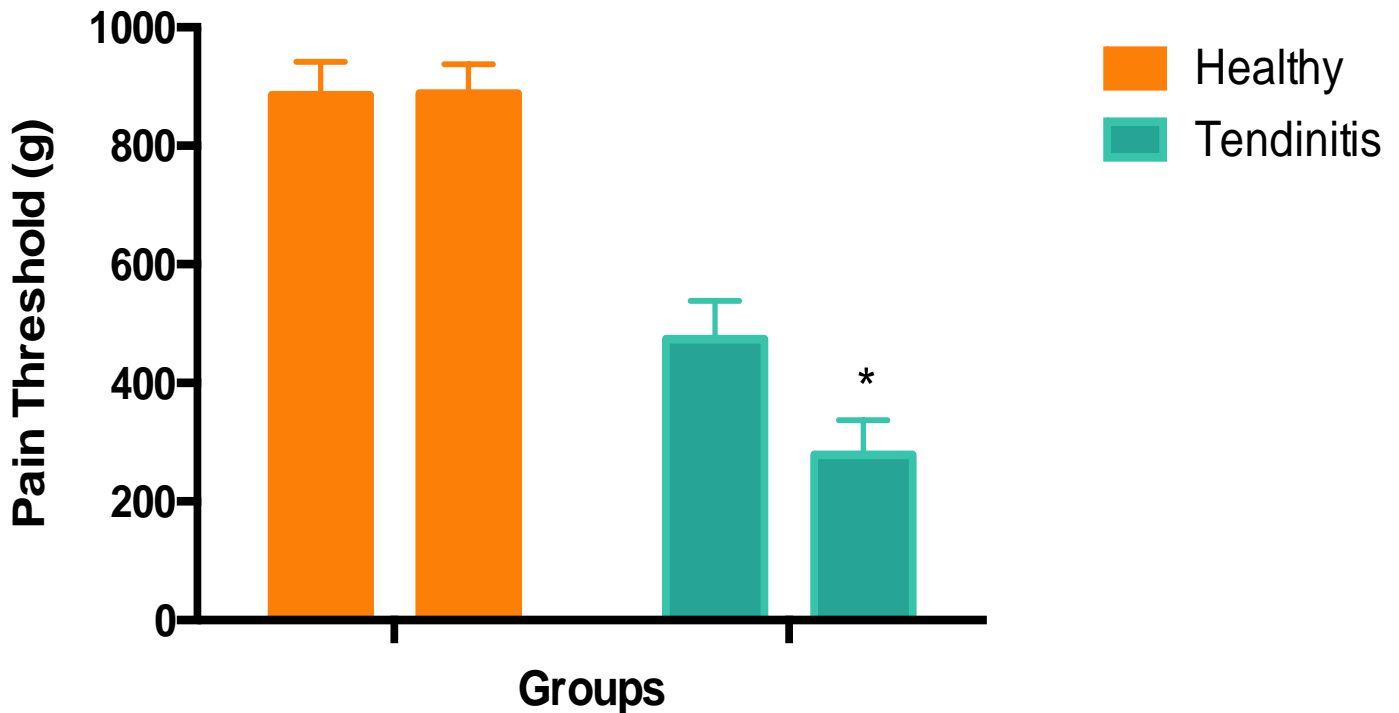


Figure 02: The pain threshold was evaluated by the electronic Von Frey test and expressed as grams of tension supported by the patient. Results are expressed as mean ± stand error of six participants in Control group (healthy tendons) and Tendinitis.

* $p < 0.05$.

Achilles Tendon Thickness

Table 2 displays the characterization regarding AT thickening. In the CG, thickening of the bilateral CT was observed on palpation in only 16.7% of the participants (n=1). Unilateral thickening was not verified in the CG. In the TG, there was thickening of the right CT in 16.7% of the participants (n=1); thickening of the left CT in 16.7% of the participants (n=1) and finally, bilateral thickening in 66.7% of the participants (n=4).

Table 2: Characterization regarding Achilles tendon thickening.

Group	Tendon Thickening		
	Right	Left	Bilateral
Control	0%	0%	0%
Tendinopathy	17%	17%	67%

Tendon Crepitation

There was no crackling in the CG. In the TG, there was crepitus in the right CT in 33.3% of the participants (n=2), in the left CT in 33.3% of the participants (n=2) and bilateral in 33.3% of the participants (n=2). It is possible to visualize the characterization of the CT in terms of crepitus in Table 3.

Table 3: Achilles tendon characterization regarding crepitus.

Crepitation on Palpation			
Group	Right	Left	Bilateral
Control	0%	0%	0%
Tendinopathy	33%	33%	33%

Arc Signal

Table 4, represented below, shows the results obtained regarding the presence of Arc Signal. None of the CG members showed a positive arch signal. In the TG, 16.7% of the participants (n=1) had an arch sign on the left CT and 16.7% of the participants (n=1) had it bilaterally. No participant showed the sign on the right.

Table 4: Presence of Arc Signal.

Presence of Arc Signal			
Group	Right	Left	Bilateral
Control	0%	0%	0%
Tendinopathy	0%	17%	17%

The Royal London Hospital Test

It is possible to visualize the results obtained in the Royal London Hospital Test in Table 5. No participant in the control group was positive in this test, while in the TG 16.7% (n=1) was positive for right CT, 16.7% (n=1) for left CT, and finally, 16.7% (n=1) bilaterally.

Table 5: Royal London Hospital Test.

Royal London Hospital Test			
Group	Right	Left	Bilateral
Control	0%	0%	0%
Tendinopathy	17%	17%	17%

Pain During Passive Dorsiflexion

None of the CG participants had pain in passive dorsiflexion. In the TG, 16.7% of participants (n=1) had pain on the left and 16.7% (n=1) had pain bilaterally. None of the TG participants had pain on the right side only, as shown in Table 6.

Table 6: Presence of pain in passive dorsiflexion.

Presence of Pain in Passive Dorsiflexion			
Group	Right	Left	Bilateral
Control	0%	0%	0%
Tendinopathy	0%	17%	17%

Pain When Lifting the Heel

The results of the tests for the presence of pain when lifting the heel are represented in Tables 7 and 8, expressing 1 cm of lifting and 2 cm, respectively. In none of the tests did the CG show pain. In both tests in the TG, there was pain on the right in 33.3% of the participants (n=2) and bilaterally in 16.7% of the participants (n=1). When lifting 1 cm, there was pain on the left in 16.7% of the participants (n=1) of the TG and when lifting 2 cm, there was pain on the left in 50% of the participants (n=3) of the TG.

Table 7: Presence of pain when lifting the heel (1cm).

Presence of pain when lifting the heel (1cm)			
Group	Right	Left	Bilateral
Control	0%	0%	0%
Tendinopathy	33,3%	16,7%	16,7%

Table 8: Presence of pain when lifting the heel (2cm).

Presence of pain when lifting the heel (2cm)			
Group	Right	Left	Bilateral
Control	0%	0%	0%
Tendinopathy	33%	17%	17%

Single Hop Test

Table 9 displays in centimeters (cm) the results obtained in the single hop test. The CG obtained an average of 105.8 cm when jumping with the right lower limb, and 106.7 cm when jumping with the left lower limb. In the TG, this average obtained very different values: 78.6 cm with the right limb and 74.8 cm with the left limb.

Table 9: Single Hop test.

Single Hop Test (cm) Average		
Group	Right	Left
Control	105,8	106,7
Tendinopathy	78,6	74,8

Infrared thermography analysis – Differences between healthy and affected tendons

Analyzes with infrared thermography were performed at 4 different points along the CT, always comparing the right limb to the left limb. It was found that while in the CG the maximum temperature difference between limbs was 0.4°C, in the TG the difference was from 1°C to 5.1°C. The Average difference in the control group was 0.24 ± 0.15 °C while in the tendinopathy group was 1.2 ± 0.9 °C.

Figure 03 demonstrates a representative thermographic image of normal legs (left image) and Tendinopathy legs (right image). As we can observe, there is a marked increase in temperature difference between the legs demonstrating the tendon inflammation in the left leg of the left panel.

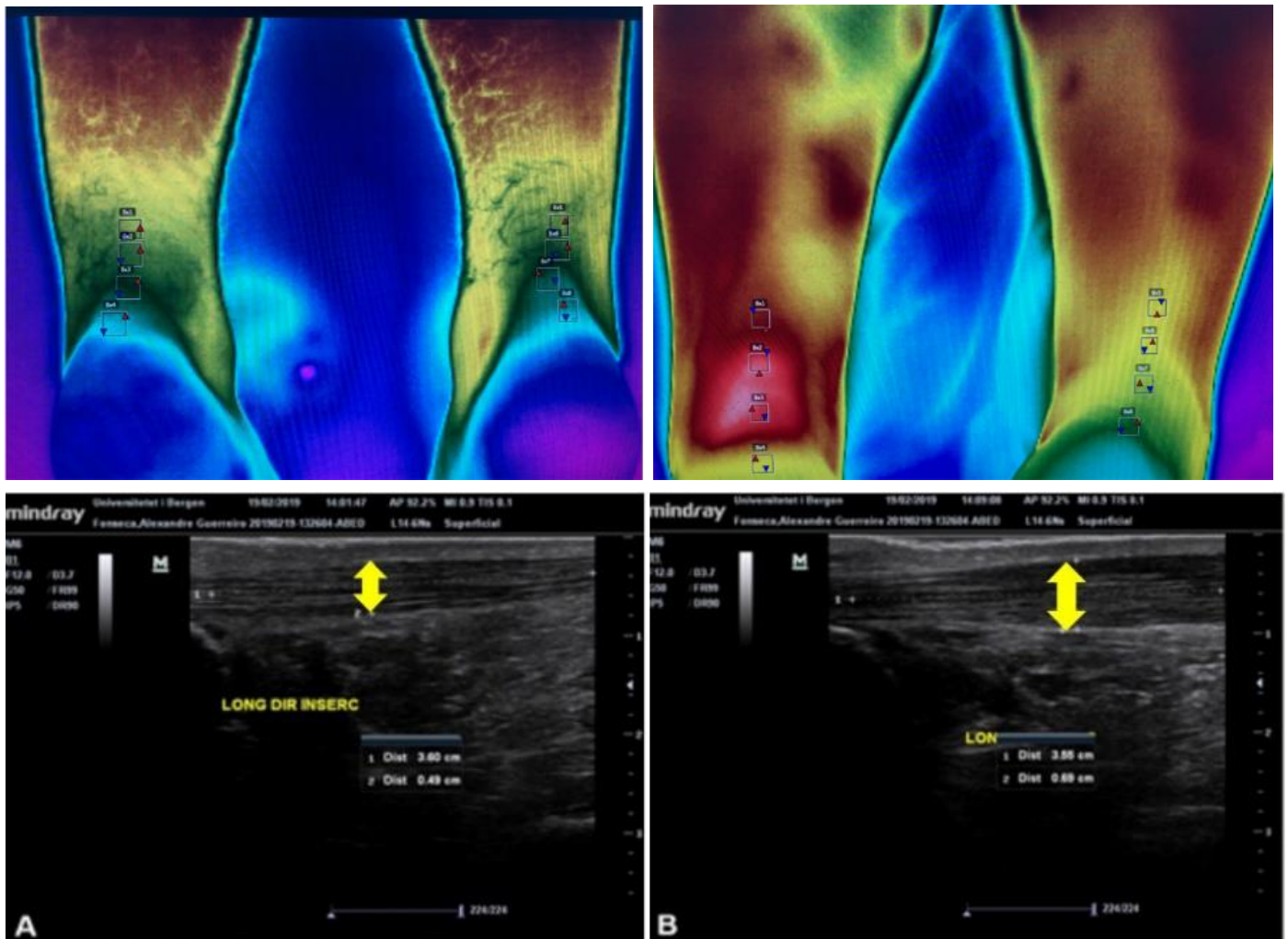


Figure 03: Representative image of Healthy tendons (left panel) and the affected (tendinopathy) tendons (right panel). The differences were confirmed by the image ultrasound showing the tendon thickening in the affected tendon (right image).

DISCUSSION

The inflammatory process is classically described as the reaction of a multicellular organism to a harmful stimulus, generated by chemical, physical, biological or mechanical agents, which may or may not be accompanied by tissue injury. It can be said that it is a defense reaction of the organism, fundamental for the maintenance of the species⁽²²⁾. The inflammatory response is classically composed of an acute phase followed (or not) by chronicity⁽²³⁾. The acute phase is a rapid response of the body to aggression, with a relatively short duration (from hours to days), characterized by vasodilation, increased vascular permeability and leakage of plasmatic fluid rich in proteins from the lumen of the blood vessel into the extravascular space, the which leads to the formation of tissue edema.

Vasodilation has the physiological objective of reducing the speed of blood flow in the inflammatory site, and together with the change in vascular permeability, it aims to allow the migration of inflammatory cells to the affected site. Obviously, all this biochemical and cellular activity results in an increase in the metabolic rate which is reflected in the increase in local temperature.

The use of infrared thermography and image analysis and processing allow us to perform biometric (quantitative) analysis of biological phenomena especially those where heat alteration represent important signs of pathological conditions. In The inflammatory process heat changes or increases are classically recognized as a cardinal sign of active inflammation. Infrared thermography has become an important tool helping in diagnosis and the treatment follow up. However, establishing and characterizing health patterns in order to differentiate from pathological conditions is central. Considering that infrared thermography is been used for decades in industry but still a non-consolidated method in health sciences, it's extremely important to characterize what is physiological and what can be considered as a pathological condition, not only in terms of temperature variations but to establish a correspondence between this new technique and classical pathological signs, here observed the Achilles tendinopathy⁽²⁴⁾.

Thermography is a non-invasive, safe, painless, non-contact and relatively inexpensive technique. The advantage of thermography is that it can be used repeatedly by repeating the test in a short period of time. Importantly, thermographic studies using an infrared camera allow archiving of acquired thermograms and the follow up of the patients' treatments⁽²⁴⁾.

In this study, it has been shown that the use of infrared thermography analysis was able to identify changes in the Achilles tendons temperature and its spatial distribution of temperature fields on the skin surface in the course tendinitis. Until this moment there are no studies known from literature which allow for quantitative evaluation temperature changes and patterns in symptomatic tendinopathy patients, supported by the classical clinical signs of inflammation in the tendons. Here, besides infrared thermography, we investigated pain at rest and provoked pain threshold, tendon thickness measured by image ultrasound and functional aspects like the single-hop test, all of them involved in the pathophysiology of the inflammatory process. Pain, edema, functionality, heat, and redness are recognized for centuries as the cardinal signs of inflammation.

Pain was assessed as referred pain at rest by the classical visual analogue scale (VAS) and electronic Von Frey algometry. The results demonstrate that affected side (tendinopathy) presented a significantly higher VAS values and reduced pain threshold indicating that pain and hypersensitivity were positive signs for inflammation. Pain analysis during functional activities such as pain in dorsiflexion and pain when lifting heel were used. It was clearly demonstrated that acute tendinopathy interferes with function, as classically proposed in the fifth cardinal sign loss of function. Tendon crepitation and increases in thickness were observed in affected legs as well as temperature increases representing tumor (edema) and vasodilation and increased metabolic activity at the inflamed area.

Finally, temperature is historically recognized as one of the most sensitive signals of inflammation^(25, 26). Altogether, eight temperature points in both legs in six patients were analyzed. The results demonstrate that healthy tendons presented an average temperature difference of 0.24 ± 0.15 °C between legs with a maximal difference of 0.4 °C.

On the other hand, unilateral tendinopathy presented an average temperature difference of 1.2 ± 0.9 °C, however, this difference could be as big as 5.1 °C.

CONCLUSION

Taken together, even for a pilot study, our results clearly demonstrate that all cardinal signs of inflammation are present in acute tendinopathy and that the non-invasive infrared thermography was sensitive to act as an important diagnostic tool.

Author's contributions: LFB, MCGS, PSLLM and FC were responsible for data collection. RABLM, IFN and JMB were responsible for the study protocol design. CRF and ASSF were responsible for statistical data analysis; PSL was responsible for the study supervision and coordination.

Financial Support: Rodrigo Alvaro B. Lopes-Martins was supported by CNPq – Research Productivity Grants.

Conflict of interest: The authors declare no conflict of interest for this manuscript.

REFERENCES

1. Maffulli, N.; Kader, D. Tendinopathy of tendo Achillis. *J. Bone. Joint. Surg.*, v. 84, n. 1, p. 1-8, 2002.
2. Paavola, M.; Kannus, P.; Järvinen, T. A.; Khan, K.; Józsa, L.; Järvinen, M. Achilles tendinopathy. *J. Bone. Joint. Surg. Am.*, v. 84-A, n. 11, p. 2062-2076, 2002.
3. Järvinen, T. A.; Kannus, P.; Maffulli, N.; Khan, K. M. Achilles tendon disorders: etiology and epidemiology. *Foot Ankle Clin.*, v. 10, n. 2, p. 255-266, 2005.
4. Lian, O.; Engebretsen, L.; Bahr, R. Prevalence of jumper's knee among elite athletes from different sports: a cross-sectional study. *Am. J. Sports Med.*, v. 33, n. 4, p. 561-567, 2005.
5. Langberg, H.; Kongsaard, M. Eccentric training in tendinopathy – more questions than answers. *Scand. J. Med. Sci. Sports*, v. 18, n. 5, p. 541-542, 2008.
6. Kraeutler Mj, Purcell Jm, Hunt Kj. Chronic Achilles Tendon Ruptures. *Foot Ankle Int.* 2017 Aug;38(8):921-929.
7. Mahan J, Damodar D, Trapana E, Barnhill S, Nuno AU, Smyth NA, Aiyer A, Jose J. Achilles tendon complex: The anatomy of its insertional footprint on the calcaneus and clinical implications. *J Orthop.* 2019 Jun 10;17:221-227.
8. Biewener AA, Farley CT, Roberts TJ, Temaner M. Muscle mechanical advantage of human walking and running: implications for energy cost. *J Appl Physiol* (1985). 2004 Dec;97(6):2266-74.
9. Benjamin M, Toumi H, Ralphs JR, Bydder G, Best TM, Milz S. Where tendons and ligaments meet bone: attachment sites ('entheses') in relation to exercise and/or mechanical load. *J Anat.* 2006 Apr;208(4):471-90.
10. Ramachandran M, Eastwood DM. Botulinum toxin and its orthopaedic applications. *J Bone Joint Surg Br.* 2006 Aug;88(8):981-7.
11. Dyson R, Buchanan M, Hale T. Incidence of sports injuries in elite competitive and recreational windsurfers. *Br J Sports Med.* 2006 Apr;40(4):346-50.
12. Luscombe KL, Maffulli N. The three in one procedure: how I do it. *Surgeon.* 2004 Feb;2(1):32-6.
13. Maffulli N, Benazzo F. Basic sciences of tendons. *Sports Med. Arthrosc.* 2002;8(1):1-5.
14. Maffulli, N.; Barrass, V.; Ewen, S. W. Light microscopic histology of achilles tendon ruptures. A comparison with unruptured tendons. *Am. J. Sports Med.*, v. 28, n. 6, p. 857-863, 2000.

15. McGarvey WC, Singh D, Trevino SG. Partial Achilles tendon ruptures associated with fluoroquinolone antibiotics: a case report and literature review. *Foot Ankle Int.* 1996 Aug;17(8):496-8.
16. Van Der Linden, P. D.; Sturkenboom, M. C.; Herings, R. M.; Leufkens, H. M.; Rowlands, S.; Stricker, B. H. Increased risk of Achilles tendon rupture with quinolone antibacterial use, especially in elderly patients taking oral corticosteroids. *Arch. Intern. Med.*, v. 163, n. 15, 1801-1807, 2003.
17. Rio E, Moseley L, Purdam C, Samiric T, Kidgell D, Pearce AJ, Jaberzadeh S, Cook J. The pain of tendinopathy: physiological or pathophysiological? *Sports Med.* 2014 Jan;44(1):9-23.
18. Gerow G, Callton M, Meyer JJ, Demchak JJ, Christiansen J. Thermographic evaluation of rats with complete sciatic nerve transection. *J Manipulative Physiol Ther.* 1990 Jun;13(5):257-61. Erratum in: *J Manipulative Physiol Ther* 1990 Nov-Dec;13(9)
19. Mangine RE, Siqueland KA, Noyes FR. The use of thermography for the diagnosis and management of patellar tendinitis. *J Orthop Sports Phys Ther.* 1987;9(4):132-40.
20. Rodríguez-Sanz D, Losa-Iglesias ME, López-López D, Calvo-Lobo C, Palomo-López P, Becerro-de-Bengoa-Vallejo R. Infrared thermography applied to lower limb muscles in elite soccer players with functional ankle equinus and non-equinus condition. *PeerJ.* 2017 May 25;5:e3388.
21. Al-Nakhli HH, Petrofsky JS, Laymon MS, Berk LS. The use of thermal infra-red imaging to detect delayed onset muscle soreness. *J Vis Exp.* 2012 Jan 22;(59):3551.
22. Tedgui A, Mallat Z. Anti-inflammatory mechanisms in the vascular wall. *Circ Res.* 2001 May 11;88(9):877-87.
23. Lawrence T, Gilroy DW. Chronic inflammation: a failure of resolution? *Int J Exp Pathol.* 2007 Apr;88(2):85-94.
24. Côte ACR, Hernandez AJ. Termografia Médica Infravermelha Aplicada A Medicina Do Esporte. *Rev Bras Med Esporte.* 2016;22(4):315-319
25. Cavaillon JM. Once upon a time, inflammation. *J Venom Anim Toxins Incl Trop Dis.* 2021 Apr 9;27:e20200147.
26. Serhan CN, Brain SD, Buckley CD, Gilroy DW, Haslett C, O'Neill LA, Perretti M, Rossi AG, Wallace JL. Resolution of inflammation: state of the art, definitions and terms. *FASEB J.* 2007 Feb;21(2):325-32.